

Atypical Presentation of Gingival Cyst of Adult- A Case Report

SANGEETHA SUBRAMANIAN¹, P TINU GEORGE², PSG PRAKASH³, NANDHINI GUNASEKARAN⁴, MONIKA SRIVASTAV⁵



ABSTRACT

Lesions of the gingiva are very common, and they vary in their clinical presentation and histological appearances. However, at times, the clinical features of these lesions appear to be similar and overlapping leading to a difficulty in diagnosis. Gingival Cyst of Adult (GCA) is a rare, abnormal, non-inflammatory lesion in the oral cavity that arises mostly from the cell rests of the dental lamina. These lesions are usually solitary, sessile, painless, slow growing swelling usually involving the attached gingiva and interdental papilla and more frequently found in the canine and premolar region of the mandible. The GCA usually does not show any radiographic evidence of bone resorption. Histopathologic presentation significantly contributes to the diagnosis of the lesion. The present case report discusses about the GCA, involving the marginal gingiva and interdental papilla on the facial aspect of maxillary central incisors region in a 37-year-old female patient. Treatment plan included scaling, root planing, re-evaluation followed by surgical excision of the lesion. The lesion was sent for histopathological examination and a final diagnosis of GCA was made. Healing was uneventful without any complications. The patient was reviewed for nine months and no recurrence of the lesion was observed during the follow-up period.

Keywords: Gingival growth, Gingival lesion, Intraoral fibroma, Non-inflammatory lesion, Odontogenic cyst, Pyogenic granuloma

CASE REPORT

A 37-year-old female patient reported to the Department of Periodontology with the chief complaint of swelling on the gums adjacent to the left upper front tooth region. As noted by the patient, the swelling was present for the past 15 days. The gingiva was apparently normal before the lesion appeared and gradually the lesion increased to attain the present size. There was no history of pain or pus discharge. Bleeding of gums only at the site of lesion was noticed by the patient during brushing. She had no significant medical history and was not under any medication.

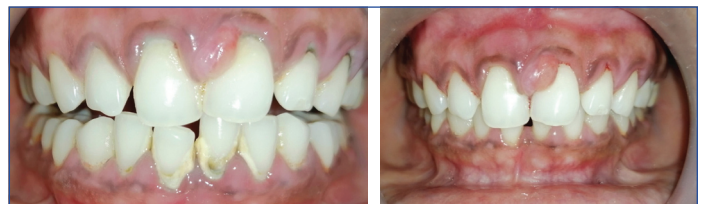On clinical examination, the lesion was present on the facial side mesial to left maxillary central incisor. The lesion was approximately 0.9x0.5 cm in size involving the marginal gingiva and interdental papilla [Table/Fig-1]. The swelling was oval in shape, fibrous in consistency, non-tender, appeared pale in colour with the adjacent gingiva with no discharge of fluids. The inter-proximal pocket depth was about 5 mm and subgingival calculus (score 3 Calculus Index-Simplified) was evident beneath the enlarged gingiva [1]. An inflammatory localised gingival enlargement in favour of pyogenic granuloma was provisionally diagnosed as these lesions occur in response to chronic irritation from subgingival calculus [2,3].

Intraoral fibromas are typically well demarcated from the surrounding tissues and mostly present with hard consistency which was not the case in the present lesion [4]. Differential diagnoses included peripheral fibroma/fibrous epulis, Lateral Periodontal Cyst (LPC), periodontal abscess, epidermoid cyst, fibroma, odontogenic keratocyst, peripheral giant cell granuloma.

Routine haematological investigation was done prior to the surgery. The total RBC count showed 4.1 million cells/ μ L with haemoglobin percentage of 12 gm/dL. Bleeding and clotting time were 2 minutes 15 seconds and 4 minutes 28 seconds, respectively. The total WBC count was 10000 cells/ μ L with the differential leucocytes count of 67% polymorphs, 30% lymphocytes and 3% eosinophils.

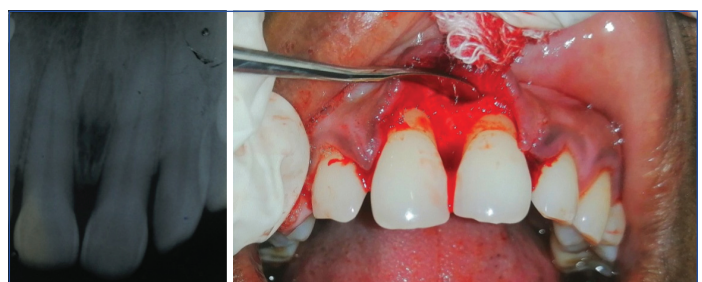Treatment plan included scaling, root planing, re-evaluation followed by surgical excision of the lesion. After scaling and root planing, oral hygiene instructions were given and thereafter the patient was

reviewed at 2nd and 4th week [Table/Fig-2]. Intraoral radiographic image taken after scaling and root planing showed radiolucency between 11 and 21 suggestive of incisive foramen and there were no signs of osseous involvement [Table/Fig-3]. Since the lesion did not regress in size, surgical excision of the lesion was planned.



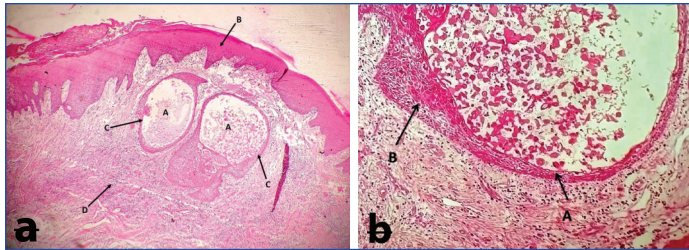
[Table/Fig-1]: Clinical image at the time of initial visit. Gingival lesion involving marginal and interdental papilla on the mesial aspect of 21. **[Table/Fig-2]:** Fourth week of review after scaling and root planing. The lesion has not regressed in size. (Images from left to right)

Under local anaesthesia (2% Lignocaine with 1:80000 adrenaline), excision of the lesion was done with a # 15 Bard Parker (BP) blade at the base of the lesion after which the flap was elevated from 11 to 22 [Table/Fig-4]. Thorough debridement of the surgical area was carried out and the flap was sutured back in position with 3.0 black silk sutures. Periodontal dressing was given. The excised specimen was stored in 10% neutral buffer formalin and sent for histopathological examination. Histopathological report revealed a mass of connective tissue covered by parakeratinised stratified squamous epithelium which appeared



[Table/Fig-3]: Radiographic image taken after SRP showed radiolucency between 11 and 21 suggestive of incisive foramen and there were no signs of osseous involvement. **[Table/Fig-4]:** Surgical elevation of the flap from 11 to 22 after excision of the lesion. (Images from left to right)

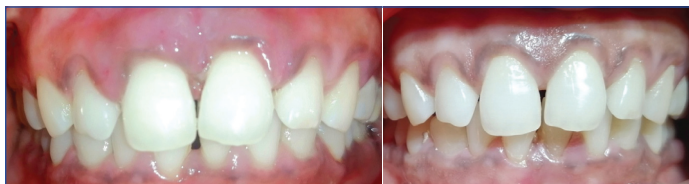hyperplastic in few areas. The underlying connective tissue showed two cystic cavities lined by keratinised squamous epithelium which was of variable thickness and contained eosinophilic material and keratin flakes [Table/Fig-5a]. The lining epithelium of the cystic cavity showed focal thickening of keratinised squamous epithelium [Table/Fig-5b]. The connective tissue showed densely arranged collagen fibres, numerous inflammatory cells predominantly lymphocytes. Numerous blood vessels with varying size and shape were also seen. On the basis of clinical examination and histopathological evidence the lesion was confirmed to be GCA.



[Table/Fig-5a]: Cystic spaces: A) seen in the connective tissue of the mucosal epithelium; B) The cystic spaces are lined by Low cuboidal to stratified squamous epithelium; C) Connective tissue shows dense inflammatory cell infiltrated and numerous blood vessels; D) (H&E, 4X). **[Table/Fig-5b]:** A) Lining epithelium exhibits focal epithelial thickenings or B) plaques (H&E, 10X).

The patient was given postoperative instructions and an analgesic, Zerodol-P, (combination of aceclofenac 100 mg and paracetamol 325 mg) was prescribed to alleviate the pain. Patient was reviewed after a week and suture removal was done [Table/Fig-6].

The patient was reviewed up to 9th month and healing was uneventful without any complications [Table/Fig-7]. Patient is still under follow-up to monitor if any recurrence of the lesion occurs.



[Table/Fig-6]: First week postoperative image after flap surgery. **[Table/Fig-7]:** Postoperative image at 9th month review. (Images from left to right)

DISCUSSION

Lesions of the gingiva are very common but vary in their clinical presentations and histopathological appearances. At times, the clinical features of these lesions appear to be similar and overlapping leading to difficulty in diagnosis [5]. One such lesion is GCA where the histopathologic presentation significantly contributes to the diagnosis of the lesion particularly if the lesion does not represent classic clinical feature. GCA is a rare, abnormal non inflammatory lesion in the oral cavity. It is an odontogenic cyst that arises either from the rests of dental lamina, heterotopic glandular elements or from displaced oral epithelium [6,7]. The frequency of the GCA accounts for 2.6% of the entire odontogenic cysts reported in India [8]. This cyst arises from the gingiva and later tends to involve the alveolar cortex [9]. This lesion is more frequently found in the canine and premolar region of the mandible and it usually involves the attached gingiva and interdental papilla [10]. In Indian population, it is reported more in females than in males in the ratio of 3:1 [8].

Gingival cyst may occur as a solitary, painless, slow growing and sessile swelling which is often left unnoticed if the lesion is relatively small in size [11]. Reports of multiple cysts have also been described in the literature [10,12-16]. Sometimes the colour of the gingival swelling appears to show a bluish hue due to the presence of cystic fluid as well as with respect to the thinning of the oral mucosa [10,11,17]. The GCA usually does not show any radiographic evidence of bone resorption. But in some cases, due to the pressure from the cyst there may be slight erosion on the surface of the bone [18,19].

The present report is a GCA, located in the marginal and interdental papilla on the facial aspect of maxillary central incisor region. Various studies have reported that the most common site of lesion is the anterior segment of mandible mostly in the incisor and canine region [8,10,20,21]. According to Giunta JL, the ratio of lesion between mandible to maxilla is 4:1 [10]. In the current case report, the lesion was reported in the maxilla adjacent to the central incisor region. Maxillary gingival cysts are usually found in the incisor, canine and premolar region [19]. This lesion commonly occurs during the 4th, 5th and 6th decade of life [12,19], whereas in the present case report, the patient is in the third decade. The size of the lesion is usually reported to be less than 5 mm in diameter and may present the same color of the adjacent normal color of the mucosa sometimes [19].

The lesion reported here was not a classic representation of GCA in the sense that it was not a fluctuant, translucent fluid filled lesion and bluish hue on the surface suggestive of a cystic lesion of the soft tissue was not noted. The lesion was oval in shape; pale in colour compared to adjacent gingiva and had a fibrous consistency involving the marginal gingiva and interdental papilla. Initially, based on the clinical appearance, the lesion was suspected to be pyogenic granuloma which is a reactive vascular lesion, most commonly appears on the gingiva. This lesion is known to arise as result of trauma or recurrent irritation, most commonly in females [22-24]. Since the patient had subgingival calculus which is a source of chronic irritation, its contribution to the development of lesion was considered. The development of this lesion is more common in circumstances where alterations in sex hormones levels are present [25]. Pyogenic granuloma clinically appears as a soft bright red swelling that may have areas of grey tinge due to ulceration and haemorrhage can be easily induced by minor trauma. However, in this case the lesion was pale in colour when compared with the adjacent gingiva [25]. Histologically, the lesion shows proliferation of endothelial cells arranged in sheets [5].

Clinically, the lesion resembled gingival fibroma; however, fibromas are usually well demarcated with firm to hard consistency [26]. GCA shows similar characteristics both clinically and morphologically to that of LPC [27]. Wysocki GP et al., in 1980 suggested that these two cysts share a common histogenesis and also the authors concluded that both the lesions arise from the rests of dental lamina [10,27,28]. The main difference is that LPC arises from proliferation of dental lamina within bone while, GCA arises from dental lamina remnant in soft tissue [13]. Therefore, GCA presents itself in soft tissue and LPC presents intra-osseously.

The histopathology of most cases with GCA reported to show an uninfamed connective tissue surrounding a lumen lined by a very thin squamoid or cuboidal epithelium [10]. The histopathology of the present case report revealed inflammatory cells mainly lymphocytes in the connective tissue, probably because the lesion is located adjacent to the inflamed interdental papilla. In concordance with our findings, Karmakar S et al., in his article, also reported that GCA microscopically appeared with a fibrous connective tissue surrounding the cystic space and also described the lumen was lined by 2-3 cells arranged from thick flat to cuboidal in shape with a loose connective tissue showing a mild chronic inflammatory cell infiltrate mainly lymphocytes with red cell extravasations [13]. Wysocki GP et al., reported 10 cases with only soft tissue lesion in the gingiva with no bony involvement [27]. Cairo F et al., stressed the need for radiographic examination to differentiate GCA from LPC [29].

Treatment of GCA is primarily by surgical excision, and the prognosis reported is satisfactory without any postoperative relapse [10,28]. In the present report, the patient was followed-up for about 9 months with no postoperative relapse. While diagnosing, it is important to keep rarer lesions of the gingiva in mind as clinical presentation may not be classical or typical for every lesion. The correlation of clinical, radiographical and histological findings would help in the confirmative diagnosis of such lesions.

CONCLUSION(S)

The diagnosis of soft tissue lesions of the gingiva may be more challenging to the clinicians sometimes based on the clinical features. For the rare developmental lesion like GCA, it becomes imperative for the dental clinicians to interpret the lesion clinically and histopathologically. If the lesion is situated in the marginal gingiva, complete debridement of the lesion by elevating a flap is vital to the establishment of a favourable gingival architecture. This measure enhances oral hygiene maintenance and prevents recurrences.

REFERENCES

- [1] Greene JG, Vermillion JR. The simplified oral hygiene index. *J Am Dent Assoc.* 1964;68(1):07-13.
- [2] Verma PK, Srivastava R, Baranwal HC, Chaturvedi TP, Gautam A, Singh A. Pyogenic granuloma-hyperplastic lesion of the gingiva. *Open Dent J.* 2012;6:153-56.
- [3] Regezi JA, Sciubba JJ, Jordan RC. *Oral pathology: Clinical pathologic considerations.* Elsevier 7th edition. 2015.
- [4] Lanjekar A, Kulkarni S, Akhade S, Sonule S, Rathod U. An unusually large irritation fibroma associated with gingiva of lower left posterior teeth region. *Case Rep Dent.* 2016;28:01-04. Doi: 10.1155/2016/5202181.
- [5] Brierley DJ, Crane H, Hunter KD. Lumps and bumps of the gingiva: A pathological miscellany. *Head Neck Pathol.* 2019;13(1):103-13.
- [6] Moskow BS, Bloom A. Embryogenesis of the gingival cyst. *J Clin Periodontol.* 1983;10(2):119-30.
- [7] Ritchey B, Orban B. Cysts of the gingiva. *Oral Surgery, Oral Surg Oral Med Oral Pathol.* 1953;6(6):765-71.
- [8] Kambalimath DH, Kambalimath HV, Agrawal SM, Singh M, Jain N, Anurag B, et al. Prevalence and distribution of odontogenic cyst in Indian population: A 10 year retrospective study. *J Maxillofac Oral Surg.* 2014;13(1):10-15.
- [9] Bhaskar SN, Laskin DM. Gingival cysts: Report of three cases. *Oral Surg Oral Med Oral Pathol.* 1955;8(8):803-07.
- [10] Giunta JL. Gingival cysts in the adult. *J Periodontol.* 2002;73(7):827-31.
- [11] Shear M, Speight P. *Cysts of the oral and maxillofacial regions.* John Wiley & Sons 4th edition; 2008.
- [12] Hegde U, Reddy R. Gingival cyst of adult-a case report with unusual findings. *Indian J Dent Res.* 2004;15(2):78-80.
- [13] Karmakar S, Nayak SU, Kamath DG. Recurrent gingival cyst of adult: A rare case report with review of literature. *J Indian Soc Periodontol.* 2018;22(6):546-50.
- [14] Wescott WB, Correll RW, Craig RM. Two fluid-filled gingival lesions in the mandibular canine-first premolar area. *J Am Dent Assoc.* 1984;108(4):653-54.
- [15] Shade NL, Carpenter WM, Delzer DD. Gingival cyst of the adult: Case report of a bilateral presentation. *J Periodontol.* 1987;58(11):796-99.
- [16] Dent CD, Rubis EJ, MacFarland PJ. Bilateral gingival swellings in the mandibular canine-premolar areas. *J Am Dent Assoc.* 1990;120(1):71-72.
- [17] Sato H, Kobayashi W, Sakaki H, Kimura H. Huge gingival cyst of the adult: A case report and review of the literature. *Asian J Oral Maxillofac Surg.* 2007;19(3):176-78.
- [18] Malali VV, Satisha TS, Jha AK, Rath SK. Gingival cyst of adult: A rare case. *J Indian Soc Periodontol.* 2012;16(3):465-68.
- [19] Deliverska EG, Gerdzhikov I. Gingival cyst of adults-two case reports and literature review. *J of IMAB.* 2018;24(2):2065-68.
- [20] Wagner VP, Martins MD, Curra M, Martins MA, Munerato MC. Gingival cysts of adults retrospective analysis from two centers in South Brazil and a review of the literature. *J Int Acad Periodontol.* 2015;17(1):14-19.
- [21] Jones AV, Craig GT, Franklin CD. Range and demographics of odontogenic cysts diagnosed in a UK population over a 30-year period. *J Oral Pathol Med.* 2006;35(8):500-07.
- [22] Saravana GH. Oral pyogenic granuloma: A review of 137 cases. *Br J Oral Maxillofac Surg.* 2009;47(4):318-19.
- [23] Kamal R, Dahiya P, Puri A. Oral pyogenic granuloma: Various concepts of etiopathogenesis. *J Oral Maxillofac Pathol.* 2012;16(1):79-82.
- [24] Marla V, Shrestha A, Goel K, Shrestha S. The histopathological spectrum of pyogenic granuloma: A case series. *Case Rep Dent.* 2016;12:01-06. Doi: 10.1155/2016/1323798.
- [25] Mortazavi H, Safi Y, Baharvand M, Rahmani S, Jafari S. Peripheral exophytic oral lesions: A clinical decision tree. *Int J Dent.* 2017;5(5):01-19.
- [26] Yadav N, Kumar A, Manohar B, Makhijani B. Irritational gingival fibroma: A case report. *Int J Dent Med Specialty.* 2017;4(2):07-10.
- [27] Wysocki GP, Brannon RB, Gardner DG, Sapp P. Histogenesis of the lateral periodontal cyst and the gingival cyst of the adult. *Oral Surg Oral Med Oral Pathol.* 1980;50(4):327-34.
- [28] Brod JM, Passador-Santos F, Soares AB, Sperandio M. Gingival cyst of the adult: Report of an inconspicuous lesion associated with multiple agenesis. *Case Rep Dent.* 2017;2017:4346130. Doi: 10.1155/2017/4346130.
- [29] Cairo F, Rotundo R, Ficarra G. A rare lesion of the periodontium: The gingival cyst of the adult-a report of three cases. *Int J Periodontics Restorative Dent.* 2002;22(1):79-83.

PARTICULARS OF CONTRIBUTORS:

1. Reader, Department of Periodontology, SRM Dental College and Hospital, Ramapuram, Tamil Nadu, India.
2. Postgraduate, Department of Periodontology, SRM Dental College and Hospital, Madurai, Tamil Nadu, India.
3. Professor, Department of Periodontology, SRM Dental College and Hospital, Ramapuram, Tamil Nadu, India.
4. Reader, Department of Oral and Maxillofacial Pathology and Microbiology, SRM Dental College and Hospital, Ramapuram, Tamil Nadu, India.
5. Postgraduate, Department of Oral and Maxillofacial Pathology and Microbiology, SRM Dental College and Hospital, Ramapuram, Tamil Nadu, India.

NAME, ADDRESS, E-MAIL ID OF THE CORRESPONDING AUTHOR:

P Tinu George,
T-11, 1st Milk Booth, Ellis Nagar, Madurai-625016, Tamil Nadu, India.
E-mail: ptinugeorge@gmail.com

PLAGIARISM CHECKING METHODS: [Jain H et al.]

- Plagiarism X-checker: Apr 30, 2021
- Manual Googling: Aug 02, 2021
- iThenticate Software: Oct 25, 2021 (11%)

ETYMOLOGY: Author Origin

AUTHOR DECLARATION:

- Financial or Other Competing Interests: None
- Was informed consent obtained from the subjects involved in the study? Yes
- For any images presented appropriate consent has been obtained from the subjects. NA

Date of Submission: **Apr 29, 2021**

Date of Peer Review: **Jun 09, 2021**

Date of Acceptance: **Sep 24, 2021**

Date of Publishing: **Nov 01, 2021**